



Dr Simon Platt

MB ChB, PGCert, FRCS, FRCS
(Tr. & Orth), FRACS (Orth)
**Orthopaedic Surgeon
(Foot & Ankle)**

Dr Simon Platt's special interests include:

- Sports injuries
- Arthroscopic (keyhole) and minimally invasive surgery
- Soft tissue injuries
- Bunions
- Acute fractures
- Reconstruction procedures
- Achilles tendon surgery.

To arrange an appointment with Dr Simon Platt, please contact:

Gold Coast Private Hospital
Specialist Suites
Ground Floor, 14 Hill Street,
Southport QLD 4215

P 07 5530 0770

F 07 5530 0687

E reception@coastfootandankle.com.au



Coast
Foot and Ankle

DR. SIMON PLATT

Gold Coast Private Hospital

14 Hill Street, Southport QLD 4215

P 07 5530 0300 | **F** 07 5530 0646

goldcoastprivatehospital.com.au

A Guide to Bunions

A Fact Sheet by Dr Simon Platt

Bunion

Hallux Valgus - commonly called a bunion, may lead to painful motion of the 1st MTP J and difficulty with shoe wear. It is typically a painful and debilitating condition for patients. However, It responds well to intervention.

The pathology is largely unknown but progressive instability at the TMT and the MTP lead to the classic deformity which generally worsens over time and may lead to arthritis at either joint as a consequence of instability.

Patients typically present with deformity and pain. Pain is generally localised to the medial eminence with or without an enlarged bursa. Patient often complain of shoes exacerbating the pain.

Examination

Typically, a prominent medial eminence (bunion) with a valgus deformity to the hallux (the big toe deviates away from the second toe) often with a pronated hallux.

Often secondary signs hammering or over riding of the second toe. Callosities on the medial border of the hallux and or callosities on the plantar aspects of the metatarsal heads.

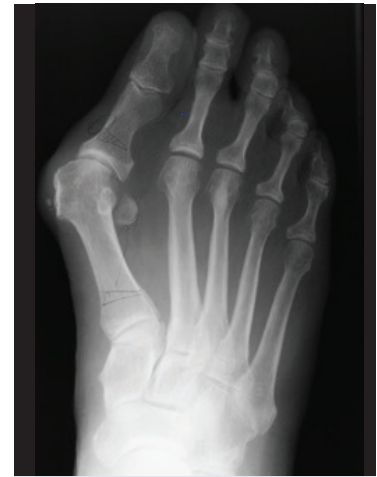The goal of treatment is to obtain a pain free foot to allow the patient to carry out their day-to-day activity, occupation and leisure activities.

As with all conditions the options are non-operative and operative.

Operative

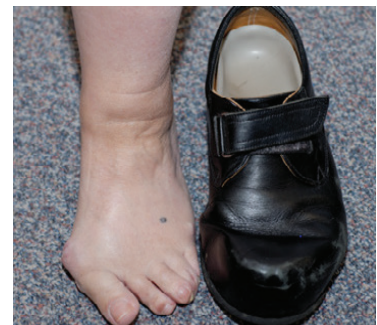Modern bunion surgery is highly effective with good outcomes. If the condition is bilateral it is a good idea to perform bilateral surgery at the same sitting.

There is no place for 'shaving' or purely soft tissue procedures on the basis that these do not correct the alignment.



Typical weight bearing radiograph confirms

- Deviation of the 1st metatarsal medially
- Lateral deviation of the proximal phalanx
- Uncovering the fibula sesamoid





Dr Simon Platt

MB ChB, PGCert, FRCS, FRCS (Tr. & Orth), FRACS (Orth)
Orthopaedic Surgeon (Foot & Ankle)

Dr Simon Platt's special interests include:

- Sports injuries
- Arthroscopic (keyhole) and minimally invasive surgery
- Soft tissue injuries
- Bunions
- Acute fractures
- Reconstruction procedures
- Achilles tendon surgery.

To arrange an appointment with Dr Simon Platt, please contact:

Gold Coast Private Hospital
 Specialist Suites
 Ground Floor, 14 Hill Street,
 Southport QLD 4215

P 07 5530 0770

F 07 5530 0687

E reception@coastfootandankle.com.au



Gold Coast Private Hospital

14 Hill Street, Southport QLD 4215
P 07 5530 0300 | **F** 07 5530 0646
goldcoastprivatehospital.com.au

In general the principle of surgery is to realign the first ray. This is most commonly carried out by an osteotomy of the metatarsal and proximal phalanx. This may be undertaken in a traditional open or minimally invasive technique. There is little evidence to suggest that minimally invasive is a better option but there is no doubt prefer the smaller scars. In severe cases a fusion operation either at the 1st MTP joint or the TMT may be required particularly where there is gross deformity and/or established arthritic change.

Non Operative

Consider a shoe with a wider and deeper toe box such as a trainer or jogger shoe which will accommodate the deformity. Toe spacers, splints and or taping/padding may also be employed.

Recovery

All modern techniques involve stable well-fixed osteotomies so allow early weight bearing in a post-operative shoe. The procedures are generally performed as a day case.

The patient will remain in the post operative sandal for 6 weeks with progressive weight bearing and active/passive ROM during this period. Patients are encouraged to keep the operated limb elevated as much as possible when resting. A wound check will be undertaken at 2 weeks.

Complications

These include:

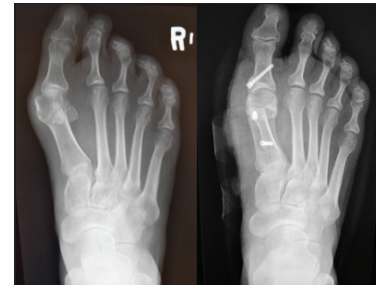- Joint stiffness
- Swelling
- Infection
- Nerve and blood vessel damage
- Recurrence of deformity
- Ongoing pain

Summary

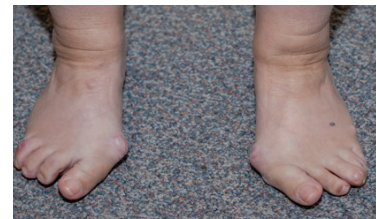
Bunion surgery by whatever means requires bony union following and osteotomy or fusion. In general, they will make a good recovery by 3 months with ongoing progression for up to 18 months post operatively.

When to Refer?

When the patient presents with symptoms, including pain and problems with shoe wear. When they ask for options for correction of the condition.



Pre and post op radiographs of scarf and Akin osteotomy. The foot has narrowed with correction of deformity. The intermetatarsal angle has reduced as has the hallu valgus angle.



Typical Hallux Valgus deformity showing Bilateral bunions, lateral deviation of all the toes and pronated halluces in a severe deformity.